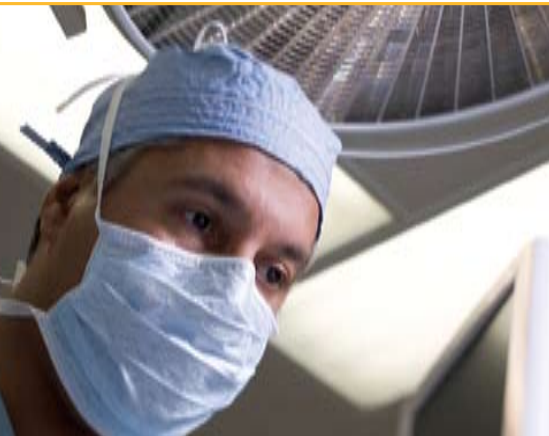

## Coblation Tonsillectomy Benefits



### Patient Benefits

- Better patient outcomes with minimal pain and fast recovery
- Reduced post-op pain and less frequent use of narcotics<sup>3</sup>
- Less incidence of postoperative nausea and throat swelling<sup>2</sup>
- Quicker return to normal diet and activities<sup>2</sup>
- Less thermal penetration to adjacent healthy tissue<sup>1</sup>
- Faster healing of tonsillar fossae<sup>3</sup>
- Less incidence of post-op neck pain<sup>4</sup>



### Surgeon Benefits

- One device for both tonsillectomy and adenoidectomy
  - Shorter operating time
- Ease of hemostasis throughout procedure
  - Variable coagulation for optimal hemostasis
  - Minimal intra-operative blood loss<sup>2</sup>
- Fewer post-op calls to physician's office during the 14-day follow-up period

### References

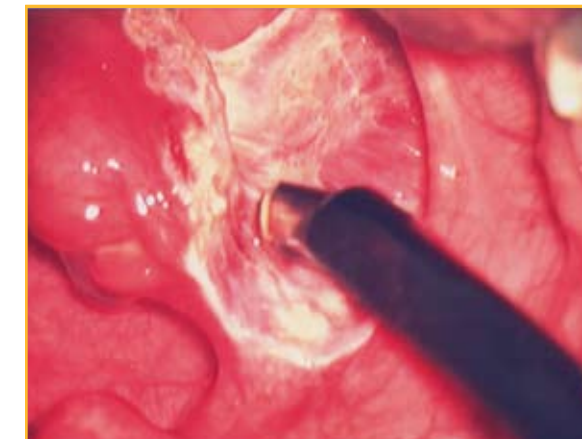- 1 Chinpaioj S, Feldman M, et al. A comparison of monopolar electrosurgery to a new multipolar electrosurgical system in a rat model. *Laryngoscope* 2001; 111; 213-217.
- 2 Stoker KE, Don DM, Kang DR et al. Pediatric total tonsillectomy using coblation electrosurgery compared to conventional electrosurgery: A prospective, controlled single-blind study. *Otolaryngology, Head and Neck Surgery* 2004; 130(6):666-675.
- 3 Temple RH, Timms MS. Paediatric coblation tonsillectomy. *Int J Pediatr Otorhinolaryngol* 2001; 61(3):195-198.
- 4 Glade R, Pearson S, Zalzal G, Choi S, Coblation adenotonsillectomy: An improvement over electrocautery technique? *Oto-HNS* (2006) 134, 852-855



## Coblation: Tonsillectomy and Adenoidectomy Surgical Pearls and Postoperative Guide

### Surgical Pearls

<b>Coblator® II Settings:</b>	<ul style="list-style-type: none"> <li>• Coblation = 6-7</li> <li>• Coagulation = 3 (increase as necessary)</li> </ul>
<b>Saline Flow:</b>	<ul style="list-style-type: none"> <li>• Continuous saline flow is required for effective ablation and coagulation and to minimize clogging.</li> </ul>
<b>Active Electrodes:</b>	<ul style="list-style-type: none"> <li>• Position Wand tip towards tonsil and away from lateral pharyngeal constrictor.</li> <li>• Hover the tip over the tissue to allow for plasma layer formation</li> <li>• Use the leading edge of the tip to make the initial incision or blunt dissection at the superior pole in order to identify the tonsillar plane.</li> </ul>
<b>Traction:</b>	<ul style="list-style-type: none"> <li>• Retract tonsil inferomedially at all times.</li> </ul>
<b>Coagulation:</b>	<ul style="list-style-type: none"> <li>• Coagulation is optimized when the Wand tip is laid flat onto the bleeder with direct pressure. Canting the tip from side-to-side may also aid in achieving hemostasis.</li> </ul>



Remember to leave a small interface between the tissue and tip of the Wand by hovering the tip over the tissue. This permits the plasma layer to form and allows for a smoother dissection.

Keep the Wand tip facing medially towards the tonsil throughout the surgical procedure.

EVac® 70 Xtra Wand tip facing medially towards the tonsil



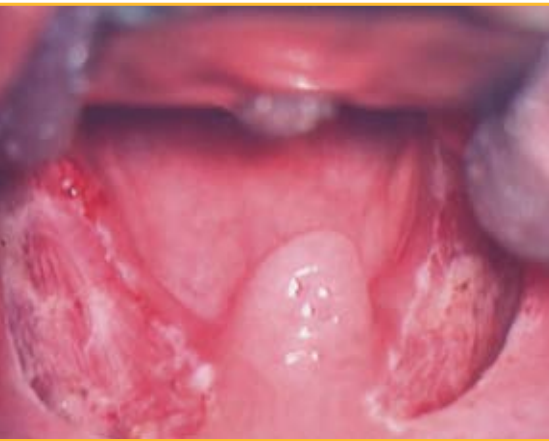**ArthroCare ENT**  
680 Vaqueros Avenue  
Sunnyvale, CA 94085-3523  
order entry **888-797-6520**  
phone 408-736-0224  
order entry fax 888-994-2782  
[www.arthrocareENT.com](http://www.arthrocareENT.com)

**ArthroCare Europe AB**  
Baggensgatan 25  
111 31 Stockholm  
Sweden  
phone +46 8 546 172 00  
fax +46 8 546 172 39  
[info@arthrocare.se](mailto:info@arthrocare.se)

**CAUTION:** Federal (USA) law restricts this device to sale by or on the order of a physician.

© 2006 ArthroCare Corporation. ArthroCare, Coblation, Coblator and EVac are trademarks and/or registered trademarks of ArthroCare Corporation.

## Post-dissection Surgery Pearls



Tonsillar fossae following Coblation Tonsillectomy

- Rough up tonsillar fossae (Yankhauer tip, 4x4 or index finger).
- Coagulate inferior and superior poles and/or any other oozing areas to ensure tonsillar fossae is dry.
  - Use a laryngeal mirror for increased visualization of underlying vessels.
- Close mouth gag for 30 seconds, open mouth and confirm field is dry.
- If necessary, repeat coagulation of the inferior and superior poles as well as in the middle of the tonsillar fossae.

## Patient Post-op Protocol

### Days 1-14:

**Oral Intake:** Fluids, Fluids, Fluids! Patients must drink throughout the recovery process. Cool, sweet drinks and soft solids work best. Water, ice cream, apple juice, ice pops, bananas, pudding, pasta, etc., all tend to be well tolerated.

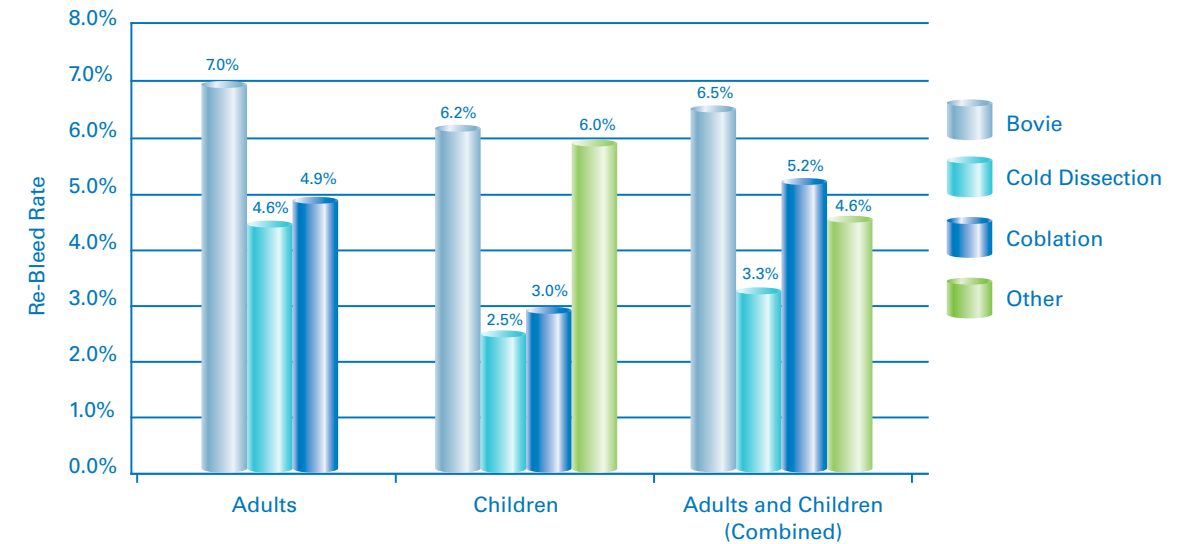
**Hard foods, sharp foods, crunchy foods, and spicy foods must be avoided.**

It is common for patients who have undergone Coblation Tonsillectomy to **feel better than expected** following their surgery, with most patients resuming a normal diet and activities within just a few days.

Therefore, it is critical that the patient avoid vigorous activity e.g., sports, running, hanging from the monkey bars, for 14 days after the procedure. This will help to reduce the risk for post-op bleeding and/or other complications.<sup>2</sup>

Potential Tonsillectomy Complications: For all tonsillectomy procedures, in addition to general anesthesia risks, 2-3% of all patients can experience post-op bleeding (up to 5-10 days after surgery). Fever may be present, and dehydration and weight loss can occur, especially among children who are reluctant to eat or drink.

## Weighted Average of Literature Tonsillectomy Re-Bleed Rates



The averages were computed for each patient group (adult, children, combined) and each of the treatment methods by weighting each rate based on the study's sample size.

### Chart References

- Beloso A, Chidambaram A, Morar P, Timms MS. Coblation tonsillectomy versus dissection tonsillectomy: postoperative hemorrhage. *Laryngoscope* 2003; 113: 2010-2013.
- Chan K, Friedman N, Allen G, Yaremchuk K, Wirtschafter A, Bikhazi N, Bernstein J, Kelley P, Lee, K. Randomized, Controlled, Multisite Study of Intracapsular Tonsillectomy Using Low-Temperature Plasma Excision. *Arch Otolaryngol Head Neck Surgery* 2004; 130: 1303-1307.
- Chang K. Randomized controlled trial of Coblation versus electrocautery tonsillectomy. *Otolaryngol Head Neck Surg* 2005; 132: 273-80.
- Collison PJ, Mettler B. Factors associated with post-tonsillectomy hemorrhage. *Ear Nose Throat J* 2000; 79: 640-2, 644, 646.
- Divi V, Benninger M. Postoperative Tonsillectomy Bleed: Coblation Versus Noncoblation. *Laryngoscope* 2005; 115: 31-33.
- Glade R, Pearson S, Zalzal G, Choi S. Coblation adenotonsillectomy: An improvement over electrocautery technique? *Otolaryngology-Head and Neck Surgery* 2006; 134: 852-855.
- Granell J, Gete P, Villafriela M, Bolanos C, Vicent JJ. Safety of outpatient tonsillectomy in children: a review of 6 years in a tertiary hospital experience. *Otolaryngol. Head Neck Surg.* 2004; 131: 383-387.
- Liu JH, Anderson KE, Willging JP, Myer CM, III, Shott SR, Bratcher GO, Cotton RT. Posttonsillectomy hemorrhage: what is it and what should be recorded? *Arch. Otolaryngol. Head Neck Surg.* 2001; 127: 1271-1275.
- Lowe D, van der MJ. Tonsillectomy technique as a risk factor for postoperative haemorrhage. *Lancet* 2004; 364: 697-702.
- Maini S, Waine E, Evans K. Increased post-tonsillectomy secondary haemorrhage with disposable instruments: an audit cycle. *Clin. Otolaryngol.* 2002; 27: 175-178.
- Montague ML, Lee MS, Hussain SS. Effect of disposable instruments on paediatric post-tonsillectomy haemorrhage rates. *Int. J. Pediatr. Otorhinolaryngol.* 2003; 67 Suppl 1: S221-S223.
- Parsons S, Cordes S, Comer C. Comparison of Posttonsillectomy Pain Using the Ultrasonic Scalpel, Coblator, and Electrocautery. *Otolaryngology-Head and Neck Surgery* 2006; 134: 106-113.
- Ranjit S, Brett RH, Lu PK, Aw CY. The incidence and management of post-tonsillectomy haemorrhage: a Singaporean experience. *Singapore Med. J* 1999; 40: 622-626.
- Smith I, Wilde A. Secondary tonsillectomy haemorrhage and non-steroidal anti-inflammatory drugs. *J Laryngol. Otol.* 1999; 113: 28-30.
- Widfuhr J, Rimmert S. Hemorrhage Following Coblation Tonsillectomy. *Annals of Otolaryngology, Rhinology, & Laryngology*, 2005; 114: 749-756.
- Windfuhr JP, Chen YS. Incidence of post-tonsillectomy hemorrhage in children and adults: a study of 4,848 patients. *Ear Nose Throat J* 2002; 81: 626-8, 630, 632.